


AMA INDICATES WHY YOU MUST VIEW SPINE PROBLEMS IN UPRIGHT FLEXION AND EXTENSION



In an important book from The American Medical Association, *Guides To The Evaluation of Permanent Impairment* (AMA Press, 2006), the authors provide ample indication why you must see the spine in flexion and extension to diagnose pathology.

“The dominant motions at both the lower cervical and entire lumbar spine, where most clinical pathology occurs, are flexion-extension” (p. 378).

Now, there’s a way you can see the spine in flexion and extension – with the nerves, discs, and other soft tissue in clear view. The revolutionary **Fonar Upright® Multi-Position™ MRI**. In fact, with the **Fonar Upright® Multi-Position™ MRI**, you can see the spine fully loaded with the weight of the body – which studies indicate creates 11 times more pressure on the discs (A. L. Nachemson, 1976; H. J. Wilke et al, 1999).

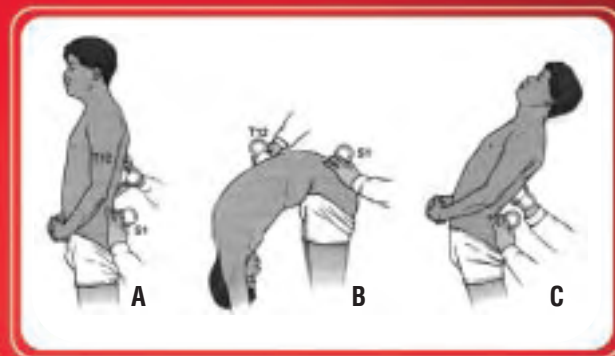
Most MRI exams are still performed in a recumbent-only MRI, and the book also notes:

“... in up to 85% of individuals who report back pain, no pain-producing pathology can be identified” (p. 566)

No wonder the director of the largest orthopedic hospital in the Netherlands and chairman of spine surgery, Dr. Paul Pavlov, stated: “... once Fonar made available upright weight-bearing MRI imaging technology, owning one for the St. Maartenskliniek “Spine Center” was not optional, but mandatory. For our hospital to continue to engage in spine surgery without it, once this new technology became available, was unacceptable.”

RANGE OF MOTION (FROM AMA BOOK): LUMBAR SPINE

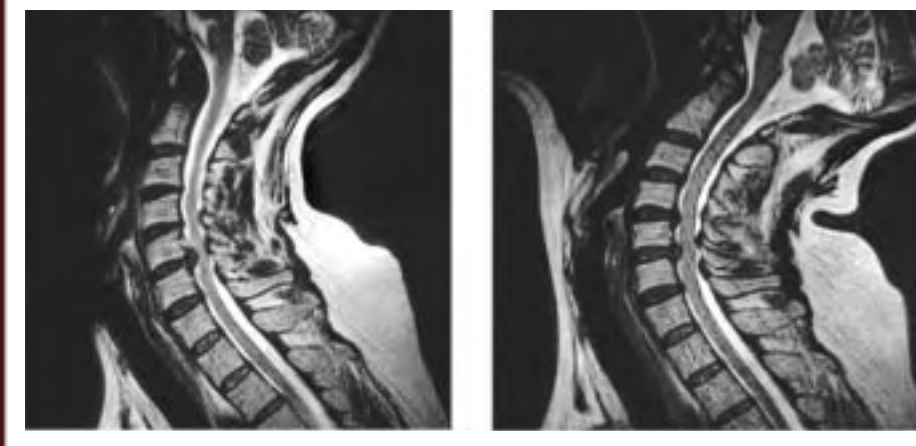
- A. NEUTRAL POSITION
- B. FLEXION
- C. EXTENSION



1 H. J. Wilke, P. Neef, M. Caimi, T. Hoogland and L. E. Claes, *Spine* 24, #8, p. 755-762, 1999. A. L. Nachemson, *Spine* 1, #1, p. 59-71

2 Case study courtesy of Richard Marks, MD, Board-Certified Orthopedic Surgeon, Up and Open Imaging, Dallas, Texas.

CASE STUDY: UNSUSPECTED DISC HERNIATION ON EXTENSION



Upright-Neutral.

Upright-Extension

For the dramatic difference in how well you can see spinal pathology with the **Fonar Upright® Multi-Position™ MRI**, here is a case study that provides a comparison of what can be seen in an upright-neutral position and in upright-extension.

A 62-year-old woman with chronic neck pain of 30 years duration that radiated into her shoulders sought upright, weight-bearing flexion-extension MRI to reveal the origin of her pain. Her neutral-sitting examination showed a C5-6 herniation, but upon extension an additional herniation appeared at C4-5.

Surgical cervical disk repair invariably includes fusion of the involved cervical level. Cervical herniation is frequently associated with spinal instability at the involved level.

Any surgeon, unaware of the herniation and potential instability at C4-5, would fuse C5-6, not knowing that a fusion of C5-6 might provoke added instability at C4-5 and more cervical symptoms. The result would be an unsuccessful surgical outcome with no explanation for the unsatisfactory result, since traditional recumbent-only MRI without extension would not have visualized the existence of the herniation at C4-5.

The necessity of seeing pathology in the position the patient experiences symptoms is made even more evident by the high incidence of failed back surgery.

The doctor who is able to see the real and complete pathology is most likely to be the one who performs the surgery. If he sees it as best he can, he is far more likely to achieve the best surgical outcome.

For the scanner nearest you, for additional information or to purchase a **Fonar Upright® Multi-Position™ MRI, call and ask to speak to a sales representative at 1-888-NEEDMRI (1-888-633-3674).**

Isn't a technology that lets you see spinal pathology better an invaluable enhancement of your practice – in fact, a necessity?



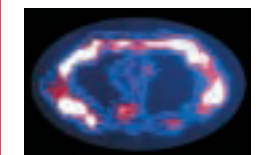
Fonar Heritage

The Inventor of MR Scanning
Timeline, Inventor Contributions



The world's first MR scanner, (Downstate Medical Center, 1977)
Smithsonian Institution, Permanent Collection

- 1969 Original Idea for MR Scanner (Grant Application to Health Research Council of the City of New York)^{1*}
- 1969 Realizes Need for a Compelling Application to Justify Building Human Scanner. Decides on Cancer Detection^{1,2}
- 1970 Key Discovery Makes the MRI Possible³
Discovery of the marked T1 and T2 signal differences among the normal tissues and also between the normal tissue and cancer tissue. Discovery enables soft-tissue detail previously absent from medical imaging, and early cancer detection; used today to detect cancers worldwide. “NMR developed into a laboratory spectroscopic technique capable of examining the molecular structure of compounds, until Damadian's ground-breaking discovery in 1971.” (*MRI From Picture to Proton*, Cambridge University Press, 2003)
- March 1971 First Article Published (*Science*)⁴
- Spring 1971 First Ever Scanning Method Proposed (*Downstate Reporter*)^{5,6,7}
- March 1972 First MR Patent Filed (3D Serial Xerox Scanning Method). Patent Issued 1974.⁸
- 1976 The Struggle Begins – Expert Declares, “Any further discussion of scanning the human body by MR (NMR) is visionary nonsense.”
- 1976 Construction of First Human MR Scanner Commences
- 1977 Construction Completed; First Human Scan Achieved: Thoracic MRI Image at T-8^{9,10,11,12}



- 1980 Fonar Installs First Commercial MRI; Initiates MRI Industry¹³
- 1997 Patent Upheld by High Court on U. S. Patents and the U. S. Supreme Court (1.1 Million Pages of Documentary Evidence Scrutinized and Argued; No Prior Art)¹⁴

*Documents at www.fonar.com

Special Offer for Physicians. Free book about the discovery of the MRI: *A Machine Called Indomitable* by Sonny Kleinfield, Reporter for The New York Times, Times Books. Call Fonar to order: 631-694-2929.

“This book is the account of the development of NMR technology and a profile of one man, Dr. Raymond Damadian, who dreamed of NMR as a weapon against cancer and struggled almost obsessively against great odds to build the first human scanner *Indomitable*.” – Library Journal

FONAR
DISCOVER THE POWER OF UPRIGHT™ IMAGING